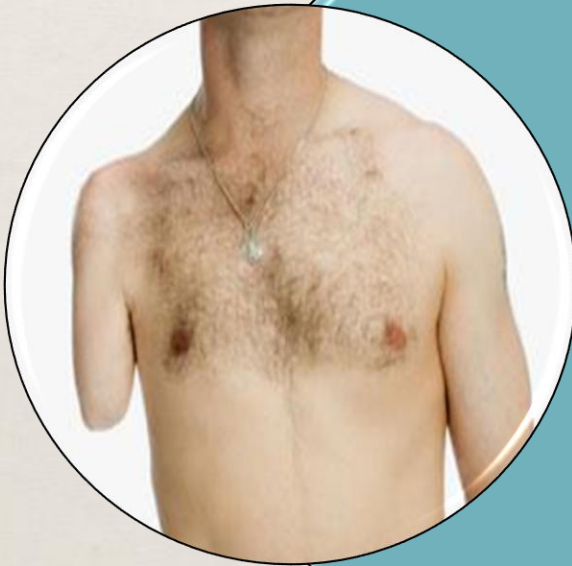

The Incongruent Self

MARY ET BOYLE, PH.D.

DEPARTMENT OF COGNITIVE SCIENCE
UCSD



“It's a **bizarre** and rare **disorder**, but its consequences can be horrific. One man ... dumped his lower leg in dry ice for several hours until doctors were **forced to amputate**. Others have resorted to wood chippers and gunshots to do away with **healthy limbs they never wanted.**”

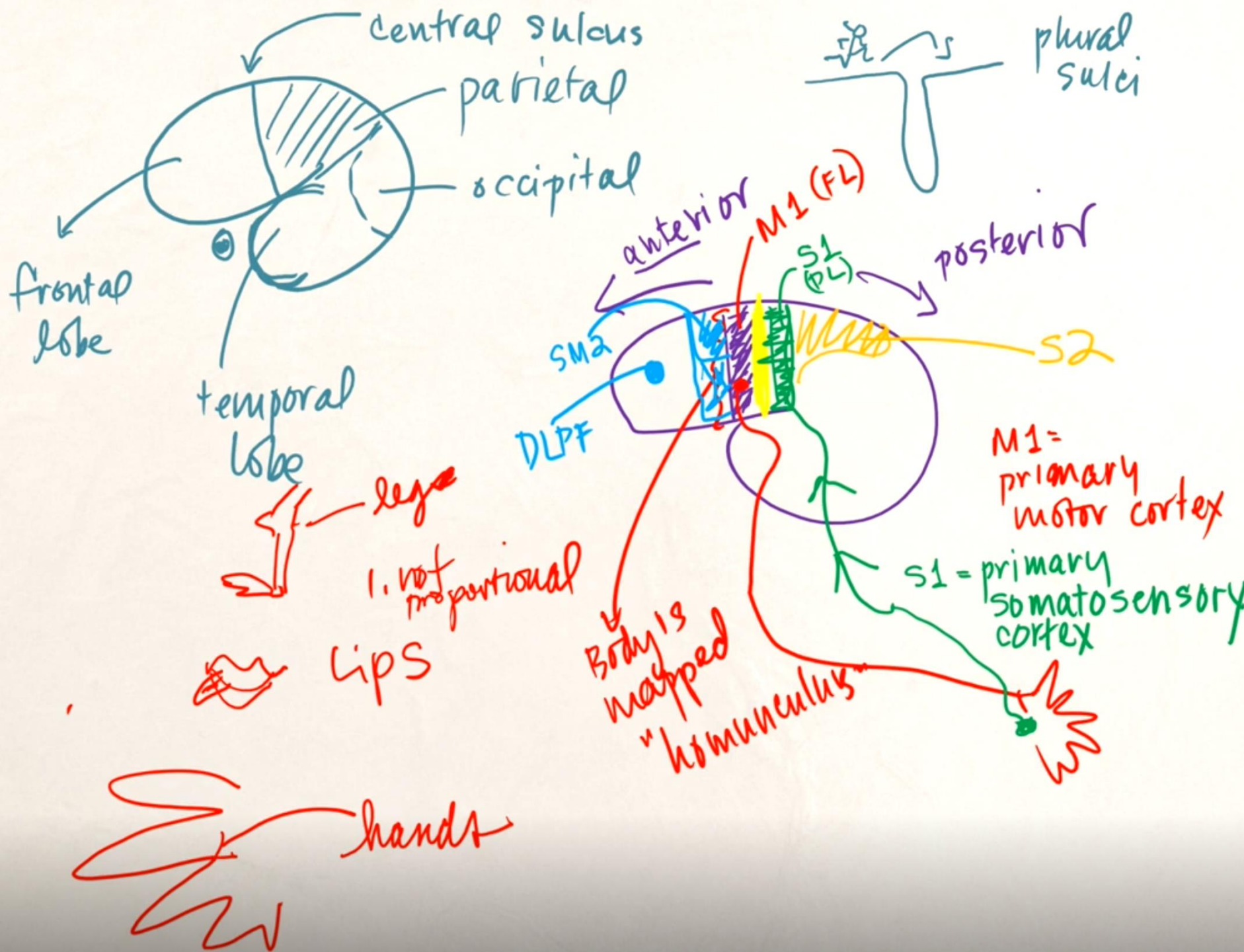
Joint Representations

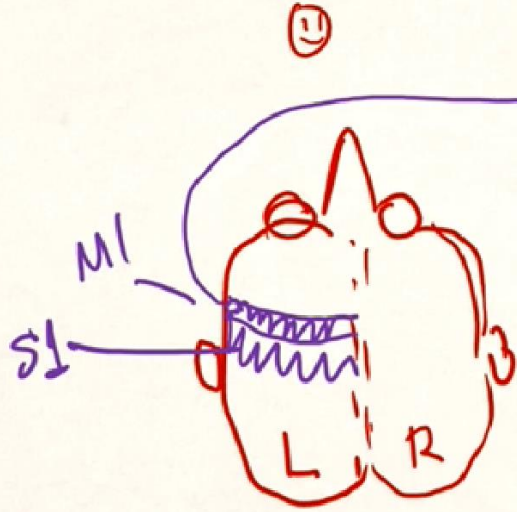
Body Schema

Proprioceptive
Sensory-Motor
Movement &
Posture
Unconscious

Body Image

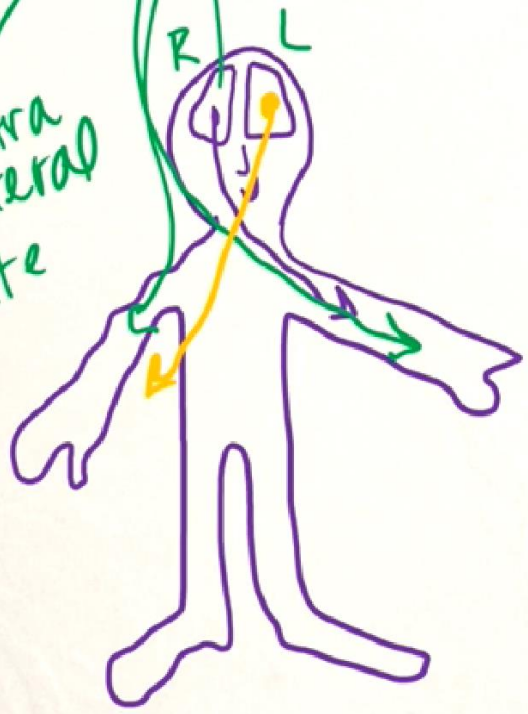
Visual
Perceptions
Beliefs
Attitudes
Conscious

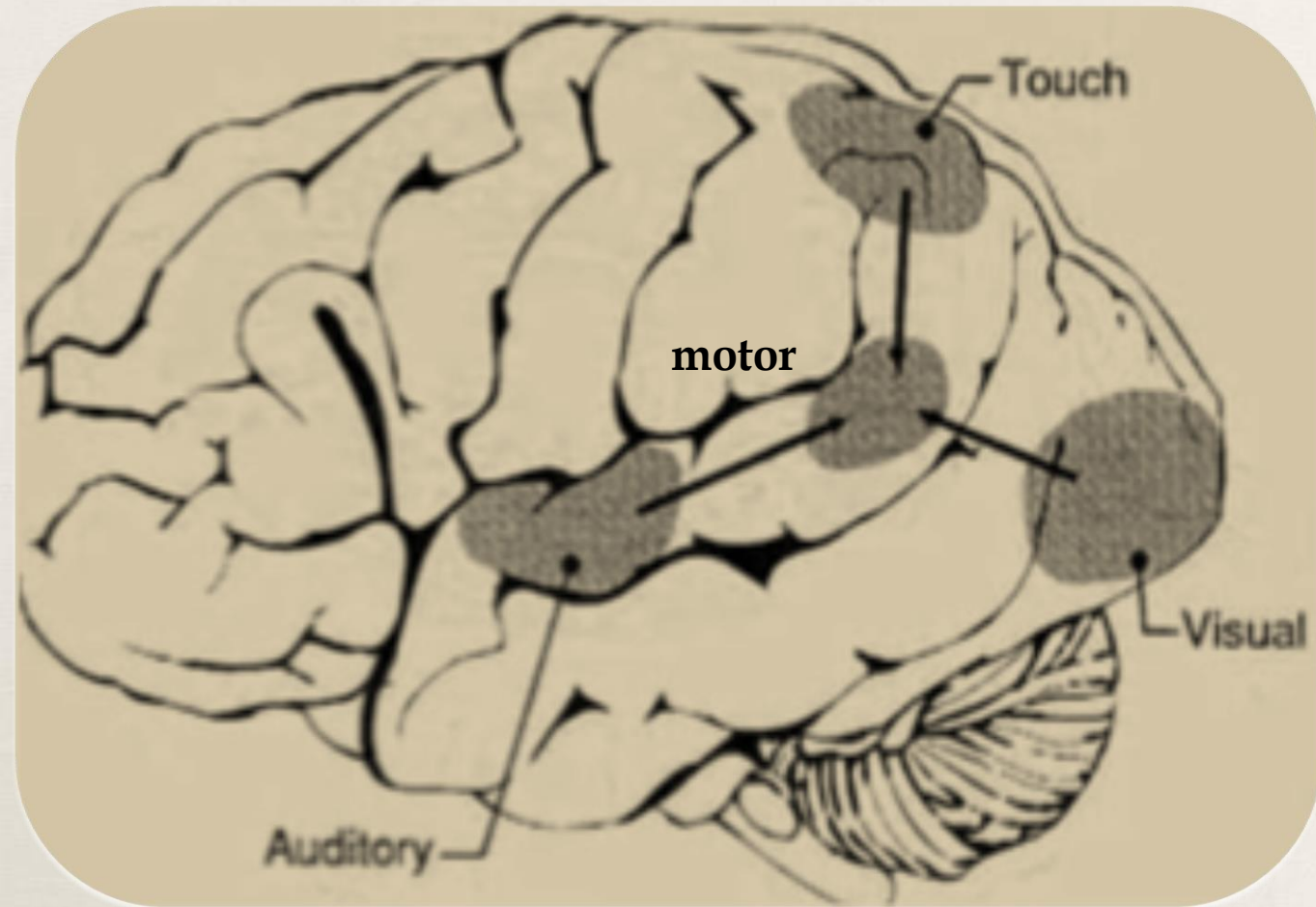




2 Homoculi
ipsilateral
same

contra lateral
opposite





somatosensory

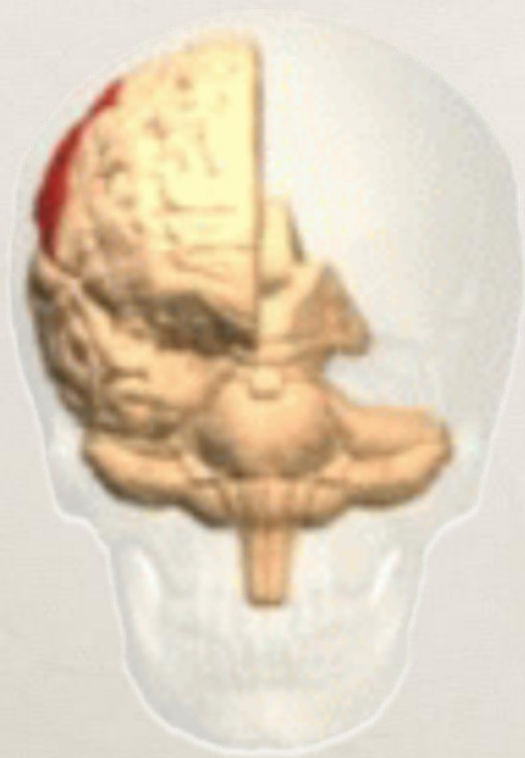visual

auditory

motor

Integration in Right-Parietal Lobe

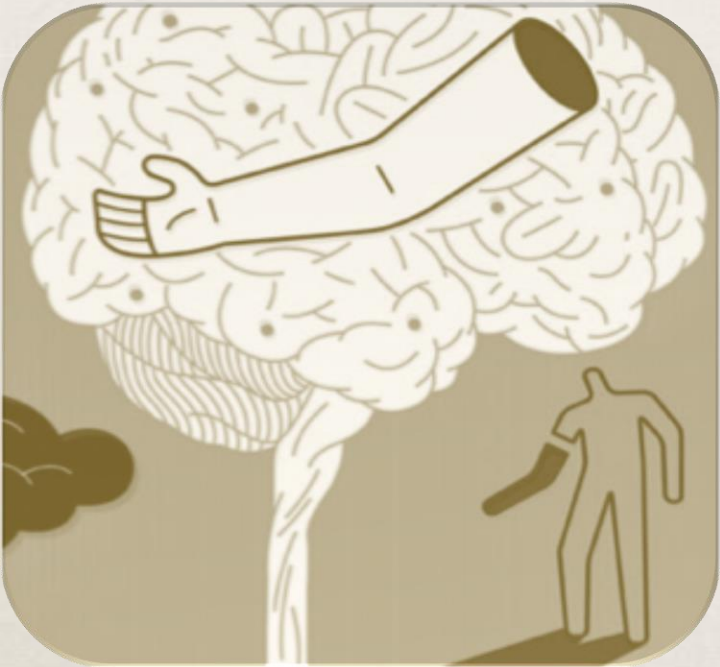
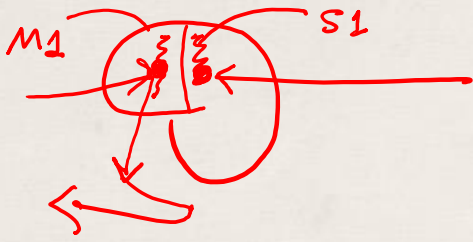
Right Parietal Lobe Damage



Loss of awareness of
his/her own body and
limbs and their
positioning in space

Denial of deficit

Disruption of experience



Supernumerary

- Phantom limb

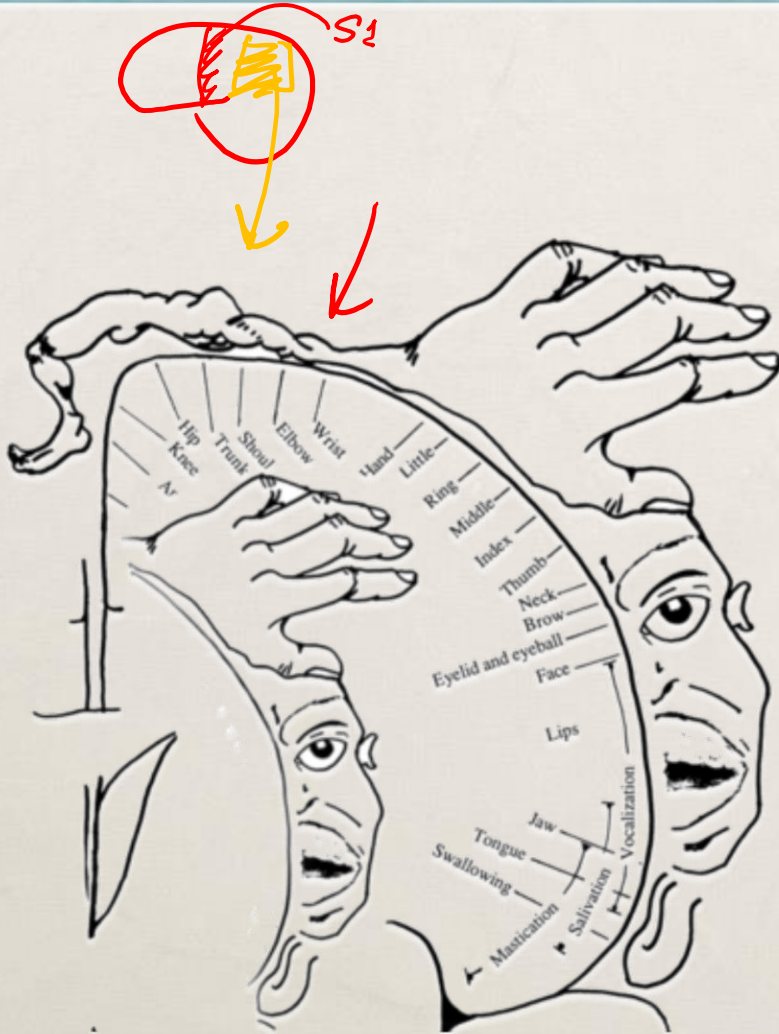


Disownership

- Somatoparaphrenia
- BIID

Positive and Negative Effects

Bilateral Representation?

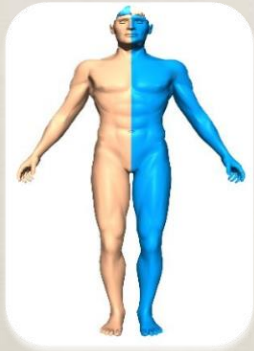

the hypothesis
that the *right*
parietal lobe
contains a
representation of
both the left
AND right body

Somatoparaphrenia



Refusal to believe that their limb belongs to them



Dis-ownership of body on contralateral side of lesion

The Man who Fell out of Bed

'Look at it!' he cried, with revulsion on his face. 'Have you ever seen such a creepy, horrible thing? I thought a cadaver was just dead. But this is uncanny! And somehow - it's ghastly - it seems stuck to me!'

He seized it with both hands, with extraordinary violence, and tried to tear it off his body, and, failing, punched it in an access of rage.


'Easy!' I said. 'Be calm! Take it easy! I wouldn't punch that leg like that.'

'And why not?' he asked, irritably, belligerently.

'Because it's your leg,' I answered. 'Don't you know your own leg?'

He gazed at me with a look compounded of stupefaction, incredulity, terror and amusement, not unmixed with a jocular sort of suspicion, 'Ah Doc!' he said. 'You're fooling me! You're in cahoots with that nurse - you shouldn't kid patients like this!'

'I'm not kidding,' I said. 'That's your own leg.' He saw from my face that I was perfectly serious - and a look of utter terror came over him. 'You say it's my leg, Doc? Wouldn't you say that a man should know his own leg?'



Oliver Sacks

Somatoparaphrenia: a body delusion.

A review of the neuropsychological literature

Giuseppe Vallar · Roberta Ronchi

Received: 30 May 2008 / Accepted: 27 August 2008 / Published online: 24 September 2008
© Springer-Verlag 2008


Abstract A review of published brain-damaged patients showing delusional beliefs concerning the contralesional side of the body (somatoparaphrenia) is presented. Somatoparaphrenia has been reported, with a few exceptions, in right-brain-damaged patients, with motor and somatosensory deficits, and the syndrome of unilateral spatial neglect. Somatoparaphrenia, most often characterized by a delusion of disownership of left-sided body parts, may however occur without associated anosognosia for motor deficits, and personal neglect. Also somatosensory deficits may not be a core pathological mechanism of somatoparaphrenia, and visual field disorders may be absent. Deficits of proprioception, however, may play a relevant role. Somatoparaphrenia is often brought about by extensive right-sided lesions, but patients with posterior (parietal-temporal), and insular damage are on record, as well as a few patients with subcortical lesions. Possible pathological factors include a

Between the end of May and the beginning of June 1669, “generosus dominus” Johannes Jakobus Schenck de Stauffenberg, who was going to leave for the fortress of Horn, suddenly fell down, hit by left hemiplegia and aphonia. Once revived, he spoke again, and his only complaint was that he referred that he had lost his left arm, and, when a servant came close to him, he grabbed firmly his (i.e., the servant’s) arm, and stated that it was his own arm, and, in order to prevent that it were taken away from him, he held it tight. (Case 169 Hemiplegia; Wepfer 1727)

Introduction

In 1942, the neurologist Josef Gerstmann (see a biographical note in Triarhou 2008) reported the cases of two right-

Hemisppatial Neglect



Left side of sensory
space becomes
non-existent
Allocentric
Egocentric

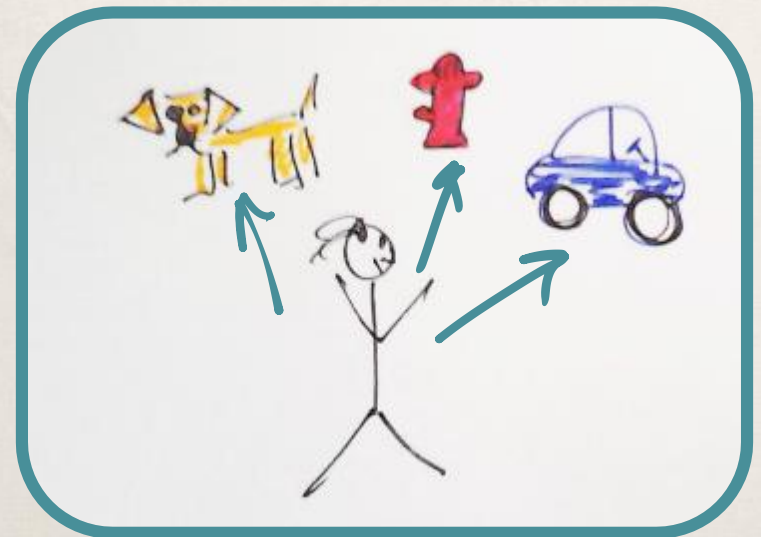
allocentric


object-
to-object



egocentric

self-to-
object





Anosognosia

E: How is your left arm?

P: Very well.

E: In what sense?

P: Ninety-five per cent.

E: Does it move?

P: It moves depending on the teacher.

E: Could you clap your hands?

P [raises her right arm]: Where has it gone? I must go and look for it [presumably referring to her left hand]. It must come back by itself.

E: Where is the left hand?

P: I do not know. I think that it has gone for a walk.

E: Has it gone by itself, detached from your body?

P: Yes.

E: At this very moment is your left hand away from you?

P: Yes.

E: Try and look towards the left.

[P looks to her left and sees her left hand.]

E: Is your left hand away?

P: Now it has come back.

E: Does it move now?

P: It is too far away to give an answer.

Unawareness
of deficit

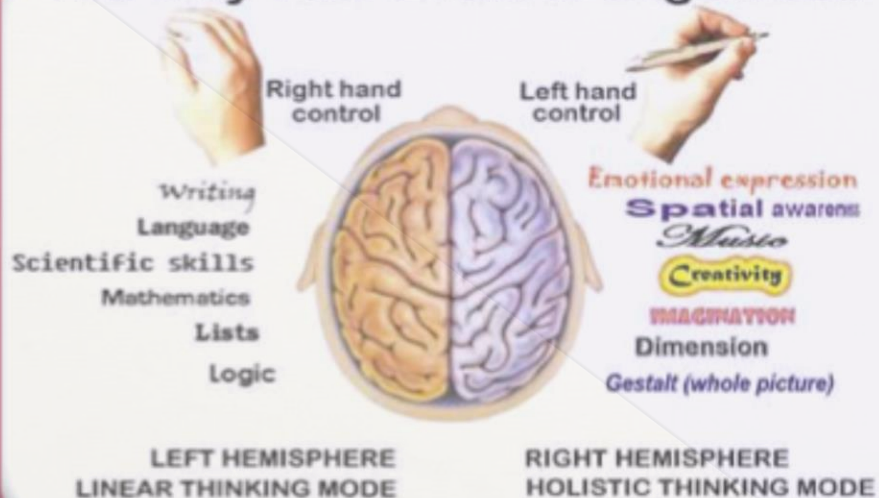
denial of
deficit

confabulation

Confabulation

information at
damage site not
transferred via
corpus callosum

The Way Your Brain Is Organised



© The Left-Handers Club (www.left-handersday.com)

left brain is clueless
to the defect

Joseph Jules François Félix Babinski



French Neurologist

Coined the term in
1914

Greek: "nosos"
disease and "gnosis"
knowledge

Apotemnophilia or BIID

(Body Integrity Identity Disorder)

overwhelming desire to
amputate one or more
healthy limbs



majority of cases it is the left limb

“Your body is not just a vehicle for your brain to cruise around in. The relationship is perfectly reciprocal: Your body and your brain exist for each other. ... Meaning is rooted in agency (the ability to act and choose), and agency depends on embodiment.”